



膀胱癌磁共振影像报告结合VI-RADS系统双参数及多参数评分应用的研究*

徐慧¹, 陈云天¹, 叶蕾¹, 郑涵瑜¹, 宋彬^{1,2}, 姚晋^{1△}

1. 四川大学华西医院放射科(成都 610041); 2. 四川大学华西三亚医院(三亚 572000)

【摘要】目的 通过回顾性研究验证双参数膀胱影像报告体系(Vesical Imaging-Reporting and Data System, VI-RADS)评分系统[T2加权(T2 weighted image, T2WI)和扩散加权(diffusion weighted image, DWI)]与多参数VI-RADS评分系统[T2WI、DWI与动态增强(dynamic contrast enhance, DCE)]在膀胱癌患者磁共振诊断价值应用的研究。**方法** 调取2020年1月-2021年12月于我院泌尿外科因膀胱癌就诊且行膀胱磁共振检查的患者影像及临床资料,最终纳入膀胱癌患者215例,其中男性183例,女性32例,平均年龄(67.60±11.42)岁。所有病例均经过病理组织切片确诊膀胱癌。两位医师双盲对多序列单独评分,对比双参数与多参数评价系统对膀胱癌的诊断效能。使用受试者工作特征(receiver operator characteristic, ROC)曲线诊断试验及Cohen's Kappa分析进行诊断效能评价及一致性分析。**结果** 两位医师使用多参数VI-RADS评分系统在总体中曲线下面积(area under the curve, AUC)及其95%置信区间为0.878(0.830~0.925)和0.856(0.805~0.907);双参数为0.889(0.844~0.934)和0.856(0.805~0.907),差异无统计学意义。在以TURBT亚组分析中差异也无统计学意义,两位医师的一致性评价Kappa值在多参数与双参数评价中分别为0.694与0.546(以VI-RADS≥3分为阳性)和0.693与0.712(以VI-RADS≥4分为阳性),且P均<0.001。**结论** VI-RADS双参数评分系统的诊断效能不劣于多参数评分系统,为对比剂过敏等无法进行增强检查的患者提供了选择。

【关键词】 VI-RADS 磁共振 膀胱癌

Application of Magnetic Resonance Imaging Report Combined With VI-RADS Bi-Parametric and Multi-Parametric Scoring Systems in Bladder Cancer Diagnosis XU Hui¹, CHEN Yuntian¹, YE Lei¹, ZHENG Hanyu¹, SONG Bin^{1,2}, YAO Jin^{1△}. 1. Department of Radiology, West China Hospital, Sichuan University, Chengdu 610041, China; 2. West China Sanya Hospital, Sichuan University, Sanya 572000, China

△ Corresponding author, E-mail: shelleyyao@163.com

【Abstract】 Objective To verify by retrospective analysis the performance of applying dual-parametric (T2 weighted image [T2WI] and diffusion weighted image [DWI]) and multi-parametric (T2WI, DWI, and dynamic contrast enhance [DCE]) evaluation systems of Vesical Imaging-Reporting and Data System (VI-RADS) in the magnetic resonance imaging (MRI) diagnosis of bladder cancer. **Methods** The imaging and clinical data of bladder cancer patients who underwent bladder MRI examination in the Department of Urology of our hospital between January 2020 and December 2021 were collected. A total of 215 bladder cancer patients, among whom there were 183 males and 32 females with an average age of (67.60±11.42) years, were included. The bladder cancer diagnosis of all the cases was verified by pathology analysis of tissue samples. Two radiologists, who were double-blinded, scored multiple sequences separately. Then, a comparative analysis was made on the diagnostic performance of dual-parametric and multi-parametric VI-RADS diagnostic scores. The diagnostic test with receiver operator characteristic (ROC) curves and Cohen's Kappa were used to evaluate the diagnostic efficacy and consistency. **Results** The area under the curve (AUC) and 95% confidence interval (CI) of the multi-parametric VI-RADS evaluation system by the two radiologists in the overall population were 0.878 (0.830-0.925) and 0.856 (0.805-0.907), while those for the bi-parametric VI-RADS evaluation system were 0.889 (0.844-0.934) and 0.856 (0.805-0.907), showing no statistically significant difference. No significant difference was observed in the subgroup analysis of patients who underwent transurethral resection of bladder tumor (TURBT). Furthermore, the Kappa values for inter-rater agreement between of the two radiologists were 0.694 and 0.546 (with the VI-RADS score ≥ 3 defined as being positive) and 0.693 and 0.712 (with the VI-RADS score ≥ 4 defined as being positive) in multi-parametric and bi-parametric evaluation, respectively (all P<0.001). **Conclusion** The bi-parametric VI-RADS scoring system can achieve a diagnostic efficacy comparable to that of the multi-parametric scoring system, offering an alternative to patients who are unable to undergo contrast-enhanced MRI due to allergic reaction to contrasts.

【Key words】 VI-RADS Magnetic resonance imaging Bladder cancer

* 四川大学华西医院学科卓越发展1-3-5工程项目(No. ZYJC21012, No. ZYGD22004)资助

△ 通信作者, E-mail: shelleyyao@163.com

出版日期: 2024-09-20

膀胱癌(bladder cancer, BCA)是最常见的十大癌症之一且是泌尿系统第二大癌症^[1]。膀胱癌根据其病灶是否侵袭膀胱壁肌层分为肌肉侵袭性膀胱癌(muscle-invasive bladder cancer, MIBC)与非肌肉侵袭性膀胱癌(non-muscle-invasive bladder cancer, NMIBC)^[2-3]。MIBC和NMIBC的治疗方式及预后均显著不同,因此可靠的术前诊断对患者治疗方案的建立及预后至关重要^[3]。基于电子计算机断层扫描(computed tomography, CT)的CT尿路成像(computed tomography urography, CTU)曾是BCA的主要术前分级手段,但是研究表明,至少有30%的BCA在术前CTU分级过低^[4-6]。随着磁共振成像(magnetic resonance imaging, MRI)技术的发展, MRI在膀胱癌早期诊断中的价值日益显著^[7]。2018年,针对临床医师难以解读MRI结果的问题,欧洲泌尿外科协会牵头建立了膀胱影像报告体系(Vesical Imaging-Reporting and Data System, VI-RADS)^[8],该体系以5分评分法对膀胱癌进行分级评分,来辅助影像诊断以提高准确率及稳定性。VI-RADS作为临床科室与放射科的沟通桥梁,显著提高了膀胱MRI的可解读性。在多项回顾、前瞻性研究后,国内外已经达成初步共识:VI-RADS ≥ 3 分的BCA存在肌层侵犯的可能性更大,该截断值诊断的受试者工作特征(receiver operator characteristic, ROC)曲线的曲线下面积(area under the curve, AUC)值在多项研究中均超过了0.85^[9-12]。

VI-RADS作为一项新兴的MRI标准,目前仍有许多细节未达成共识。其中之一就是是否需要VI-RADS评分中加入动态增强(dynamic contrast enhance, DCE)扫描。有研究认为,基于T2加权(T2 weighted image, T2WI)和扩散加权(diffusion weighted image, DWI)两个序列,可以在不注射增强钆对比剂的同时,达到不劣于T2加权、扩散加权和动态增强3个序列的诊断效果,并且避免钆对比剂带来的风险^[13-14]。但是,此类研究普遍存在一些不足之处:首先就是研究的样本量普遍偏小,因此最后得到的证据的说服力有待增强。此外,目前研究均未对已有的患者进行亚组分析。但是,从生理病理学机制上来说,某些曾经接受过经尿道膀胱肿瘤切除术(transurethral resection of bladder tumor, TURBT)的患者(如二次电切,或首次电切后复发)的膀胱壁存在纤维瘢痕增生,与初发肿瘤患者的膀胱壁微环境存在较大差异,因此应该对这两个患者是否需要接受增强检查进行单独的亚组分析。综上,本研究将通过回顾性研究,横向对比双参数VI-RADS评价系统(T2WI与DWI评分体系)及多参数VI-RADS评价系统(T2WI、DWI与DCE评分体系)在综合及

各类亚组中的诊断效能,为双参数MRI在膀胱癌诊治中的应用提供更准确的证据以及适应证。

1 资料与方法

1.1 受试对象

本研究为回顾性研究,已通过四川大学华西医院生物学医学伦理审查委员会批准(2022年审939号)。

调取2020年1月-2021年12月于我院泌尿外科因膀胱癌就诊且行膀胱MRI检查的患者影像及临床资料。纳入标准:患者行膀胱MRI增强检查;MRI检查前1周内未行灌注化疗或活检;MRI的影像质量符合VI-RADS评分标准;病理组织切片确诊膀胱癌。排除标准:患者行MRI检查前已接受全身系统治疗(如放疗、化疗、免疫治疗等);患者术后病理结果无法获取;MRI扫描禁忌证;严重系统疾病,如:肝肾系统疾病,心脑血管疾病等。

1.2 MRI数据采集及分析

1.2.1 图像采集

患者于我院3.0T MRI进行膀胱癌术前检查,使用脊柱线圈及体部线圈。扫描主要参数如下:T2WI轴位(重复时间5 000 ms,恢复时间123 ms,层厚3.6 mm);T1WI轴位(重复时间512 ms,恢复时间13 ms,层厚3.6 mm);DWI轴位(重复时间2 542 ms,恢复时间461 ms,层厚3.6 mm, b值0、800、1 400 s/mm²);DCE(重复时间4.5 ms,恢复时间1.8 ms,层厚2 mm),具体参见表1。对比剂使用钆对比剂(钆喷酸葡胺20 mL : 9.38 g)。最终成像质量由一位诊断经验超过5年的放射医师进行评价,采用5分成像法,成像质量 ≥ 4 分视为合格。

表 1 多参数MRI扫描参数
Table 1 Multiparametric MRI protocol at 3.0T

Parameter	T2WI	T1WI	DWI	DCE-MRI
TR/ms	5000	512	2542	4.5
TE/ms	123	13	461	1.8
Flip angle/degree	111	111	-	15
FOV/cm	24	26	32	36
Matrix	256×384	224×320	128×128	192×256
Slice thickness/mm	3.6	3.6	3.6	2
Spacing/mm	1	1	1	-
Number of excitations	2	2	-	1
b value/(s/mm ²)	-	-	0, 800, 1 400	-

MRI: magnetic resonance imaging; TR: repetition time; TE: echo time; FOV: field of view; T2WI: T2-weighted imaging; DWI: diffusion-weighted imaging; DCE: dynamic contrast enhanced.

1.2.2 VI-RADS评分

由研究者将纳入患者影像资料进行匿名分类处理, 利用西门子影像系统进行阅片, 由两位工作经验5年以上的放射科泌尿影像医师分别对T2WI、DWI及DCE三组序列进行影像VI-RADS评分(如存在多病灶, 则对最大病灶

进行评分)。后由研究者根据VI-RADS评分规则得出双参数MRI评分及多参数MRI评分, 详见图1。每组序列评分间隔2个月, 用于印象冲洗, 避免记忆影响。VI-RADS双参数MRI评分包括T2WI与DWI评分体系; VI-RADS多参数MRI评分包括T2WI、DWI与DCE评分体系。

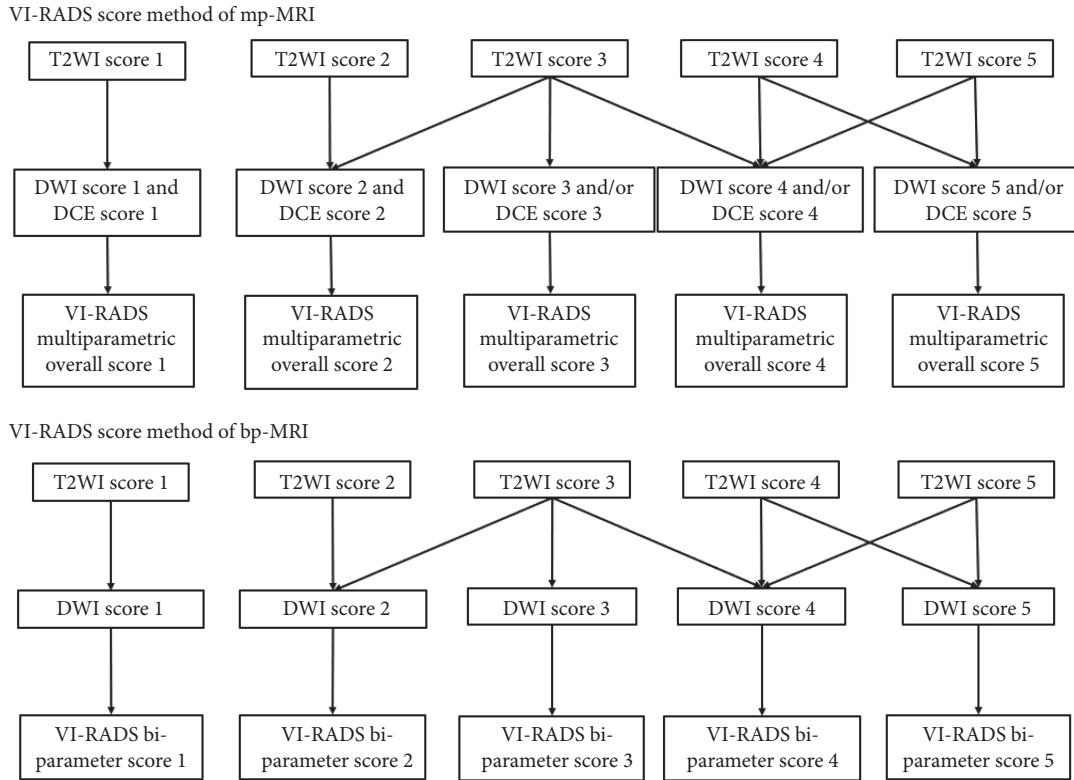


图 1 多参数及双参数评分方法示意图

Fig 1 Schematic diagram of the scoring method

VI-RADS: Vesical Imaging-Reporting and Data System; mp-MRI: multiparametric magnetic resonance imaging; bp-MRI: bi-parametric magnetic resonance imaging; T2WI: T2-weighted imaging; DWI: diffusion-weighted imaging; DCE: dynamic contrast enhanced.

1.2.3 影像特征提取

由一位泌尿影像医师记录患者影像病灶个数, 形态特征, 测量在磁共振动态增强影像中病灶最大直径。

1.2.4 结局指标

采用患者术后病理结果为金标准。主要结局指标为双参数与多参数的VI-RADS评分预测膀胱肌层侵犯的准确性[用ROC曲线下面积(area under the curve, AUC)进行评价]; 次要结局指标为双参数与多参数的VI-RADS评分不同读者间的一致性(用Kappa值进行评价)。

1.3 统计学方法

使用IBM SPSS statistic 25软件进行数据分析。

1.3.1 诊断试验

分别计算在双参数与多参数的VI-RADS评分系统评级为3及4分时, 两位医师读片评分的诊断为的灵敏度、特异度、阳性预测值、阴性预测值和准确度。使用ROC曲线

分别检测双参数与多参数VI-RADS评分系统为3及4分的AUC以评估该系统诊断准确性。

1.3.2 一致性评价

使用Cohen's Kappa评估两位阅片者之间的一致性。用来衡量两位读片者之间的一致程度(Kappa ≥ 0.75时表示结果一致性较好, 0.4 ≤ Kappa < 0.75表示一致性中等, 0 ≤ Kappa < 0.4时表示一致性较差), 排除偶然性。P < 0.05为差异有统计学意义。

2 结果

2.1 人口学资料及临床病理结果

本研究最终共纳入膀胱癌患者215例, 其中男性183例, 女性32例, 平均年龄为(67.60 ± 11.42)岁, 其中最小年龄为31岁, 最大为93岁。其中病理为MIBC的患者有102例[男87例, 女15例, 年龄平均(67.13 ± 12.35)岁], NMIBC

患者113例[男96例,女17例,平均年龄(66.97±12.12)岁],其中多发病灶63例,其中病灶直径均值为(2.13±2.0) cm。

2.2 双参数与多参数VI-RADS评分系统的诊断效能表现

采用ROC曲线评估在双参数与多参数VI-RADS评分系统在膀胱癌中的诊断价值,放射科医师1评价的2种模式的AUC的差异无统计学意义,AUC均值均达到了0.85;放射科医师2评价的2种模式的AUC的差异无统计学意义,AUC均值均达到或者接近0.85。详见表2、图2。

表2 ROC曲线评估双参数与多参数的VI-RADS评分系统在膀胱癌中的诊断价值

Table 2 Using ROC curve to evaluate the performance of mp-MRI and bp-MRI VI-RADS for diagnosing bladder cancer

Index	AUC of radiologist 1 (95% confidence interval)	AUC of radiologist 2 (95% confidence interval)
mp-MRI	0.878 (0.830-0.925)	0.856 (0.805-0.907)
bp-MRI	0.889 (0.844-0.934)	0.856 (0.805-0.907)

AUC: area under the curve; the other abbreviations are explained in the note to Fig 1.

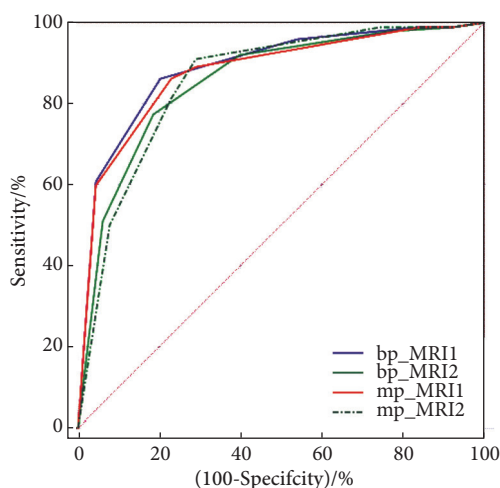


图2 两名放射科医师MRI VI-RADS评分的ROC曲线

Fig 2 The ROC curve of overall MRI VI-RADS scores given by the two radiologists

ROC: receiver operator characteristic; the other abbreviations are explained in the note to Fig 1. mp-MRI1, bp-MRI1, mp-MRI2, and bp-MRI2 represent mp-MRI and bp-MRI scores given by radiologist 1 and radiologist 2.

2.3 两种VI-RADS评分在不同截断值中的诊断试验结果

分别针对两位医师VI-RADS评分为3分及4分计算诊断的敏感度、特异度、阳性预测值、阴性预测值和准确度,得出:当以VI-RADS评分3分为截断值时,放射科医师1的诊断多参数评分的敏感度、特异度、阳性预测值、阴性预测值和准确度为89.20%、70.80%、73.39%、87.91%和79.50%,双参数评分为96.10%、46.00%、61.64%、55.91%和69.77%;与此同时,放射科医师2的数值分别为:多参数91.20%、70.80%、73.81%、89.89%和80.47%,双参数92.20%、60.20%、67.63%、89.47%和75.35%。对于两位诊断医师,双参数相较于多参数VI-RADS评分敏感度有提高,但特异度降低。

当以VI-RADS评分4分为截断值时,放射科医师1诊断多参数评分的敏感度、特异度、阳性预测值、阴性预测值和准确度为86.30%、77.00%、77.19%、86.14%和81.40%,双参数评分为86.30%、79.60%、79.28%、86.54%和82.79%;与此同时,放射科医师2的数值分别为:多参数81.40%、77.00%、76.15%、82.08%和79.07%,双参数77.50%、81.40%、79.00%、80.00%和79.53%,从数据可以看出,双参数相较于多参数VI-RADS评分特异度有提高。详见表3。

2.4 亚组分析

分析电切术后患者,以患者有无电切及电切术后时间分为4个亚组进行对比评价,见表4。两位放射科医师使用多参数及双参数VI-RADS评分诊断膀胱癌,在无手术史患者亚组中、1年内电切患者亚组中、180 d内电切患者亚组中、90 d内电切患者亚组中,其AUC值差异均无统计学意义,AUC均值均大于0.8。且4个亚组间AUC差异均无统计学意义。

2.5 两位医师VI-RADS评分一致性

两位医师的评分四格表如表5所示。两位医师的Kappa一致性检验中,以VI-RADS评分≥3诊断为膀胱癌时,多参数及双参数VI-RADS评分的一致性统计Kappa值分别为0.694与0.546,以VI-RADS评分≥4诊断为膀胱癌时,多参数及双参数VI-RADS评分的一致性统计Kappa值

表3 使用VI-RADS评分进行双参数及多参数MRI评分结果 (n=215)

Table 3 The scores of VI-RADS according to mp-MRI and bp-MRI (n=215)

VI-RADS	Radiologist 1					Radiologist 2				
	Sens/%	Spec/%	PPV/%	NPV/%	Accuracy/%	Sens/%	Spec/%	PPV/%	NPV/%	Accuracy/%
Mp-MRI overall score=3	89.20	70.80	73.39	87.91	79.50	91.20	70.80	73.81	89.89	80.47
Bp-MRI overall score=3	96.10	46.00	61.64	55.91	69.77	92.20	60.20	67.63	89.47	75.35
Mp-MRI overall score=4	86.30	77.00	77.19	86.14	81.40	81.40	77.00	76.15	82.08	79.07
Bp-MRI overall score=4	86.30	79.60	79.28	86.54	82.79	77.50	81.40	79.00	80.00	79.53

Sens: sensitivity; Spec: specificity; PPV: positive predictive value; NPV: negative predictive value; the other abbreviations are explained in the note to Fig 1.

表 4 4个亚组中VI-RADS评分在双参数与多参数以中诊断膀胱癌的效能 (ROC曲线)

Table 4 Efficacy of VI-RADS score in the diagnosis of bladder cancer in four subgroups with bp-MRI and mp-MRI (ROC curve)

VI-RADS	AUC (95% CI)			
	Patient without TURBT (n=82)	Patient underwent TURBT within a year (n=99)	Patient underwent TURBT within half a year (n=80)	Patient underwent TURBT within 3 months (n=59)
Mp-MRI of radiologist 1	0.885 (0.796-0.945)	0.849 (0.770-0.927)	0.850 (0.764-0.937)	0.835 (0.728-0.941)
Bp-MRI of radiologist 1	0.879 (0.788-0.941)	0.868 (0.793-0.943)	0.868 (0.785-0.951)	0.851 (0.748-0.954)
Mp-MRI of radiologist 2	0.858 (0.763-0.925)	0.840 (0.755-0.926)	0.868 (0.782-0.954)	0.826 (0.714-0.938)
Bp-MRI of radiologist 2	0.848 (0.752-0.918)	0.854 (0.775-0.934)	0.868 (0.782-0.953)	0.838 (0.729-0.947)
P	>0.05	>0.05	>0.05	>0.05

TURBT: transurethral resection of bladder tumor; AUC: area under the curve; CI: confidence interval; the other abbreviations are explained in the note to Fig 1.

表 5 两位医师的VI-RADS评分结果

Table 5 The VI-RADS scores given by 2 radiologists

	Radiologist 1								
	VI-RADS ≥ 3 defined as positive				VI-RADS ≥ 4 defined as positive				
	Mp-MRI VI-RADS score		Bp-MRI VI-RADS score		Mp-MRI VI-RADS score		Bp-MRI VI-RADS score		
	+	-	+	-	+	-	+	-	
Radiologist 2	+	109	17	128	11	95	14	90	10
	-	15	74	31	45	19	87	21	94

All abbreviations are explained in the note to Table 2.

分别为0.693与0.712,且P值均小于0.001,两位医师间的VI-RADS评分一致性中等。

3 讨论

本研究系统对比了在膀胱癌患者中应用双参数与多参数VI-RADS评分效能对评估膀胱癌是否合并肌层侵犯的准确性是否存在差别。本研究发现,双参数VI-RADS评分在评估膀胱癌是否合并肌层侵犯中,不劣于多参数MRI的VI-RADS评分。同时,该研究首次关注了有TURBT史的患者能否应用双参数MRI进行VI-RADS评估,结果证明,在有TURBT史的患者中,双参数MRI的诊断效能仍保持稳定,且不劣于多参数VI-RADS。

本研究结果提示双参数VI-RADS诊断效能与多参数VI-RADS诊断效能相当,这一结果与既往的许多小样本研究结果相符^[14]。双参数MRI能够降低MRI影像检查的临床成本,避免患者对比剂相关不良事件的发生,并对对比剂过敏、肝肾功能较差无法行对比增强影像检查的患者提供了检查可能,从而提高该检查与VI-RADS系统的适用范围。为了进一步验证结果的准确性,本研究分别以VI-RADS评分3分及4分为诊断标准,验证了各序列诊断的准确性,结果表明,相比VI-RADS 3分,VI-RADS 4分的诊断标准降低了诊断的敏感度,但特异度有所提高;对于放射科医师,诊断的准确度有提升。此外,课题组还查

阅了关于VI-RADS评分的临床研究^[8, 15-30],并对其中的结果分亚组进行荟萃分析,同时评估了以VI-RADS 3分与4分为分界线的诊断效能,其结果与本研究结果相同,荟萃分析结果见网络资源附件。

膀胱癌极易复发,因此大量患者在病程中会接受多次TURBT与MRI评估。患者在接受TURBT后,术区会形成纤维瘢痕,可能会对弥散成像的结果产生干扰。但是目前尚未有针对此类患者是否仍适用于双参数VI-RADS评估的研究发表。本研究基于回顾性队列,发现无论是180 d内接受TURBT的患者(此时膀胱壁主要是肉芽组织为主),或者是1年内接受TURBT的患者(此时膀胱壁已形成纤维组织),双参数VI-RADS评估的诊断效能均不劣于多参数。因此,本研究结果认为对于在MRI评估前有TURBT病史的患者,只要无血凝块残留,仍可用双参数VI-RADS进行评估。

本研究仍有一些不足之处。首先,本研究是回顾性研究,因此不可避免地会受到常见回顾性研究偏倚的影响,如患者膀胱的充盈程度不同、患者对比剂注入的系统不同、患者MRI扫描的具体机型不同,后续可通过前瞻性的研究获得更加稳定的证据。此外,本研究仅分析了系统治疗前的患者,对于系统治疗后的患者,目前也推荐采用VI-RADS评估,但是由于本中心尚未收集到足够用于分析的系统治疗接受MRI评估的患者,因此未进行此类

患者的分析。

综上,对于膀胱癌患者的术前评估,基于双参数VI-RADS评分准确性不劣于基于多参数VI-RADS评分。并且在有TURBT手术史的患者中,上述结论保持不变。后续应通过开展前瞻性、大样本的多中心研究,进一步明确双参数MRI VI-RADS的应用边界,在不降低诊断准确性的同时,尽量降低患者就诊的时间与经济成本,为对比剂过敏等无法进行增强检查的患者提供选择。

* * *

作者贡献声明 徐慧负责论文构思、正式分析、研究方法、软件、初稿写作和审读与编辑写作,陈云天负责调查研究、研究项目管理、监督指导和审读与编辑写作,叶蕾负责调查研究、研究项目管理和审读与编辑写作,郑涵瑜负责研究方法、软件和验证,宋彬负责经费获取、提供资源和监督指导,姚晋负责论文构思、数据审编、提供资源、监督指导和验证。所有作者已经同意将文章提交给本刊,且对将要发表的版本进行最终定稿,并同意对工作的所有方面负责。

Author Contribution XU Hui is responsible for conceptualization, formal analysis, methodology, software, writing--original draft, and writing--review and editing. CHEN Yuntian is responsible for investigation, project administration, supervision, and writing--review and editing. YE Lei is responsible for investigation, project administration, and writing--review and editing. ZHENG Hanyu is responsible for methodology, software, and validation. SONG Bin is responsible for funding acquisition, resources, and supervision. YAO Jin is responsible for conceptualization, data curation, resources, supervision, and validation. All authors consented to the submission of the article to the Journal. All authors approved the final version to be published and agreed to take responsibility for all aspects of the work.

利益冲突 所有作者均声明不存在利益冲突

Declaration of Conflicting Interests All authors declare no competing interests.

参 考 文 献

- [1] SIEGEL R L, MILLER K D, JEMAL A. Cancer statistics, 2020. *CA Cancer J Clin*, 2020, 70(1): 7-30. doi: 10.3322/caac.21590.
- [2] BABJUK M, BURGER M, CAPOUN O, *et al.* European Association of Urology guidelines on non-muscle-invasive bladder cancer (Ta, T1, and Carcinoma *in Situ*). *Eur Urol*, 2022, 81(1): 75-94. doi: 10.1016/j.eururo.2021.08.010.
- [3] MAISCH P, RETZ M, GSCHWEND J E, *et al.* Clinical practice guidelines for bladder cancer: a systematic review and meta-analysis using the AGREE II instrument. *Urol Int*, 2021, 105(1/2): 31-40. doi: 10.1159/000509431.
- [4] PANER G P, MONTIRONI R, AMIN M B. Challenges in pathologic staging of bladder cancer: proposals for fresh approaches of assessing pathologic stage in light of recent studies and observations pertaining to bladder histoanatomic variances. *Adv in Anat Pathol*, 2017, 24(3): 113-127. doi: 10.1097/PAP.000000000000152.
- [5] VERMA S, RAJESH A, PRASAD S R, *et al.* Urinary bladder cancer: role of MR imaging. *Radiographics*, 2012, 32(2): 371-387. doi: 10.1148/rg.322115125.
- [6] DUTTA S C, SMITH J A, SHAPPELL S B, *et al.* Clinical under staging of high risk nonmuscle invasive urothelial carcinoma treated with radical cystectomy. *J Urol*, 2001, 166(2): 490-493. doi: 10.1016/S0022-5347(05)65969-1.
- [7] ABD-ALAZEEZ M, AHMED H U, ARYA M, *et al.* Can multiparametric magnetic resonance imaging predict upgrading of transrectal ultrasound biopsy results at more definitive histology? *Urol Oncol*, 2014, 32(6): 741-747. doi: 10.1016/j.urolonc.2014.01.008.
- [8] PANEBIANCO V, NARUMI Y, ALTUN E, *et al.* Multiparametric magnetic resonance imaging for bladder cancer: development of VI-RADS (vesical imaging-reporting and data system). *Eur Urol*, 2018, 74(3): 294-306. doi: 10.1016/j.eururo.2018.04.029.
- [9] HUANG S, BAIN J, YIU T W, *et al.* Accuracy of the Vesical Imaging-Reporting and Data System (VIRADS) for pre-treatment staging of bladder cancer in an Australian cohort. *J Med Imaging Radiat Oncol*, 2022, 66(3): 370-376. doi: 10.1111/1754-9485.13317.
- [10] GHANSHYAM K, NACHIKET V, GOVIND S, *et al.* Validation of vesical imaging reporting and data system score for the diagnosis of muscle-invasive bladder cancer: a prospective cross-sectional study. *Asian J Urol*, 2022, 9(4): 467-472. doi: 10.1016/j.ajur.2021.06.001.
- [11] AHN H, KIM T M, HWANG S I, *et al.* Tumor contact length with bladder wall provides effective risk stratification for lesions with a VIRADS score of 2-3. *Eur Radiol*, 2023, 33(12): 8417-8425. doi: 10.1007/s00330-023-09925-1.
- [12] DEL GIUDICE F, FLAMMIA R S, PECORARO M, *et al.* The accuracy of vesical imaging-reporting and data system (VI-RADS): an updated comprehensive multi-institutional, multi-readers systematic review and meta-analysis from diagnostic evidence into future clinical recommendations. *World J Urol*, 2022, 40(7): 1617-1628. doi: 10.1007/s00345-022-03969-6.
- [13] MENG X, HU H, WANG Y, *et al.* Accuracy and challenges in the vesical imaging-reporting and data system for staging bladder cancer. *J Magn Reson Imaging*, 2022, 56(2): 391-398. doi: 10.1002/jmri.28064.
- [14] YE L, CHEN Y, XU H, *et al.* Biparametric magnetic resonance imaging assessment for detection of muscle-invasive bladder cancer: a systematic review and meta-analysis. *Eur Radiol*, 2022, 32(9): 6480-6492. doi: 10.1007/s00330-022-08696-5.
- [15] ARITA Y, SHIGETA K, AKITA H, *et al.* Clinical utility of the vesical imaging-reporting and data system for muscle-invasive bladder cancer between radiologists and urologists based on multiparametric MRI including 3D FSE T2-weighted acquisitions. *Eur Radiol*, 2021, 31(2): 875-883. doi: 10.1007/s00330-020-07153-5.
- [16] AHN H, HWANG S I, LEE H J, *et al.* Quantitation of bladder cancer for the prediction of muscle layer invasion as a complement to the vesical imaging-reporting and data system. *Eur Radiol*, 2021, 31(3): 1656-1666. doi: 10.1007/s00330-020-07224-7.

- [17] KIM S H. Validation of vesical imaging reporting and data system for assessing muscle invasion in bladder tumor. *Abdom Radiol*, 2020, 45(2): 491–498. doi: [10.1007/s00261-019-02190-1](https://doi.org/10.1007/s00261-019-02190-1).
- [18] HONG S B, LEE N K, KIM S, *et al*. Vesical imaging-reporting and data system for multiparametric MRI to predict the presence of muscle invasion for bladder cancer. *J Magn Reson Imaging*, 2020, 52(4): 1249–1256. doi: [10.1002/jmri.27141](https://doi.org/10.1002/jmri.27141).
- [19] WANG Z, SHANG Y, LUAN T, *et al*. Evaluation of the value of the VI-RADS scoring system in assessing muscle infiltration by bladder cancer. *Cancer Imaging*, 2020, 20(1): 26. doi: [10.1186/s40644-020-00304-3](https://doi.org/10.1186/s40644-020-00304-3).
- [20] DELLI PIZZI A, MASTRODICASA D, MARCHIONI M, *et al*. Bladder cancer: do we need contrast injection for MRI assessment of muscle invasion? A prospective multi-reader VI-RADS approach. *Eur Radiol*, 2021, 31(6): 3874–3883. doi: [10.1007/s00330-020-07473-6](https://doi.org/10.1007/s00330-020-07473-6).
- [21] BARCHETTI G, SIMONE G, CERAVOLO I, *et al*. Multiparametric MRI of the bladder: inter-observer agreement and accuracy with the Vesical Imaging-Reporting and Data System (VI-RADS) at a single reference center. *Eur Radiol*, 2019, 29(10): 5498–5506. doi: [10.1007/s00330-019-06117-8](https://doi.org/10.1007/s00330-019-06117-8).
- [22] DEL GIUDICE F, BARCHETTI G, De BERARDINIS E, *et al*. Prospective assessment of vesical imaging reporting and data system (VI-RADS) and Its clinical impact on the management of high-risk non-muscle-invasive bladder cancer patients candidate for repeated transurethral resection. *Eur Urol*, 2020, 77(1): 101–109. doi: [10.1016/j.eururo.2019.09.029](https://doi.org/10.1016/j.eururo.2019.09.029).
- [23] LIU S, XU F, XU T, *et al*. Evaluation of vesical imaging-reporting and data system (VI-RADS) scoring system in predicting muscle invasion of bladder cancer. *Transl Androl Urol*, 2020, 9(2): 445–451. doi: [10.21037/tau.2020.02.16](https://doi.org/10.21037/tau.2020.02.16).
- [24] MAKBOUL M, FARGHALY S, ABDELKAWI I F. Multiparametric MRI in differentiation between muscle invasive and non-muscle invasive urinary bladder cancer with vesical imaging reporting and data system (VI-RADS) application. *Br J Radiol*, 2019, 92(1104): 20190401. doi: [10.1259/bjr.20190401](https://doi.org/10.1259/bjr.20190401).
- [25] MARCHIONI M, PRIMICERI G, DELLI PIZZI A, *et al*. Could bladder multiparametric MRI be introduced in routine clinical practice? Role of the new VI-RADS score: results from a prospective study. *Clin Genitourin Cancer*, 2020, 18(5): 409–415.e1. doi: [10.1016/j.clgc.2020.03.002](https://doi.org/10.1016/j.clgc.2020.03.002).
- [26] SAKAMOTO K, ITO M, IKUTA S, *et al*. Detection of muscle-invasive bladder cancer on biparametric MRI using vesical imaging-reporting and data system and apparent diffusion coefficient Values (VI-RADS/ADC). *Bladder Cancer*, 2020, 6(2): 161–169. doi: [10.3233/BLC-190267](https://doi.org/10.3233/BLC-190267).
- [27] UENO Y, TAMADA T, TAKEUCHI M, *et al*. VI-RADS: multiinstitutional multireader diagnostic accuracy and interobserver agreement study. *Am J Roentgenol*, 2021, 216(5): 1257–1266. doi: [10.2214/AJR.20.23604](https://doi.org/10.2214/AJR.20.23604).
- [28] METWALLY M I, ZEED N A, HAMED E M, *et al*. The validity, reliability, and reviewer acceptance of VI-RADS in assessing muscle invasion by bladder cancer: a multicenter prospective study. *Eur Radiol*, 2021, 31(9): 6949–6961. doi: [10.1007/s00330-021-07765-5](https://doi.org/10.1007/s00330-021-07765-5).
- [29] ETXANO J, RODRÍGUEZ-VIGIL B, PÉREZ F, *et al*. Vesical imaging-reporting and data system (VI-RADS®): experiencia inicial en la clasificación del cáncer de vejiga músculo-infiltrante. *Actas Urol Esp (Engl Ed)*, 2021, 45(4): 320–325. doi: [10.1016/j.acuro.2020.10.004](https://doi.org/10.1016/j.acuro.2020.10.004).
- [30] AKCAY A, YAGCI A B, CELEN S, *et al*. VI-RADS score and tumor contact length in MRI: a potential method for the detection of muscle invasion in bladder cancer. *Clin Imaging*, 2021, 77: 25–36. doi: [10.1016/j.clinimag.2021.02.026](https://doi.org/10.1016/j.clinimag.2021.02.026).

(2024-05-19收稿, 2024-06-07修回)

编辑 吕熙



开放获取 本文使用遵循知识共享署名—非商业性使用4.0国际许可协议(CC BY-NC 4.0), 详细信息请访问

<https://creativecommons.org/licenses/by/4.0/>。

OPEN ACCESS This article is licensed for use under Creative Commons Attribution-NonCommercial 4.0 International license (CC BY-NC 4.0). For more information, visit <https://creativecommons.org/licenses/by/4.0/>.

© 2024 《四川大学学报(医学版)》编辑部 版权所有

Editorial Office of *Journal of Sichuan University (Medical Sciences)*